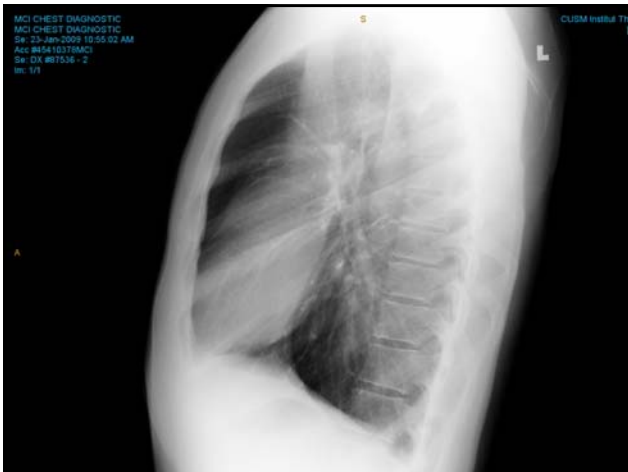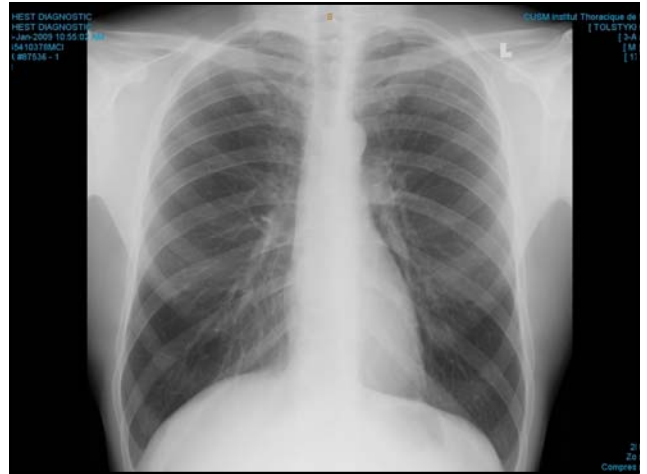
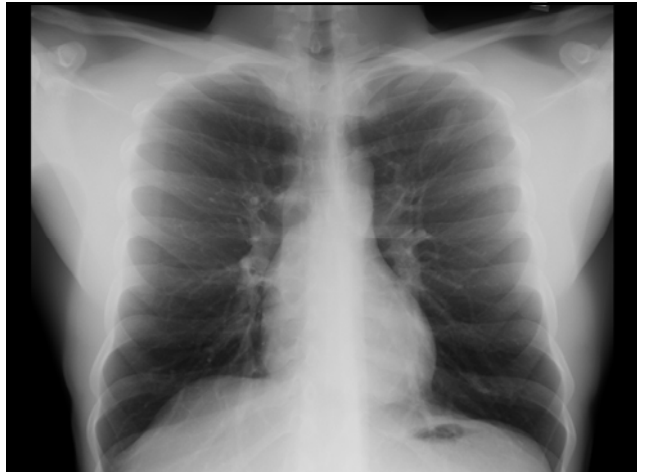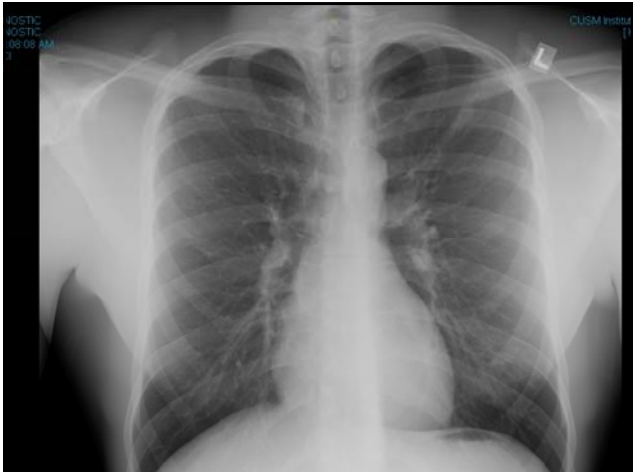

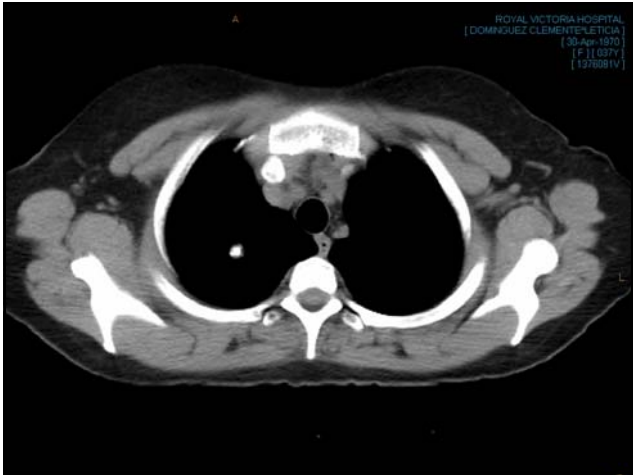


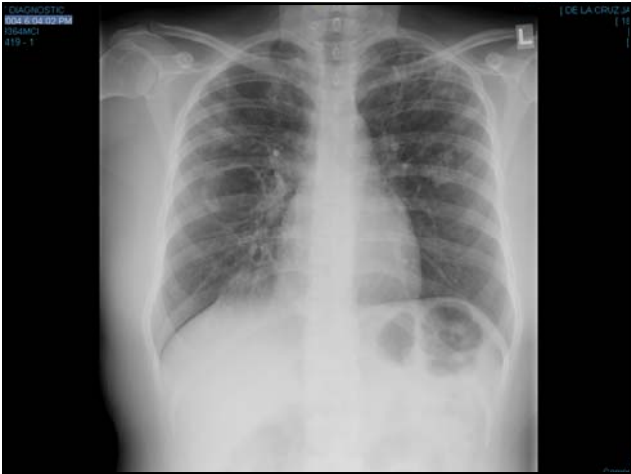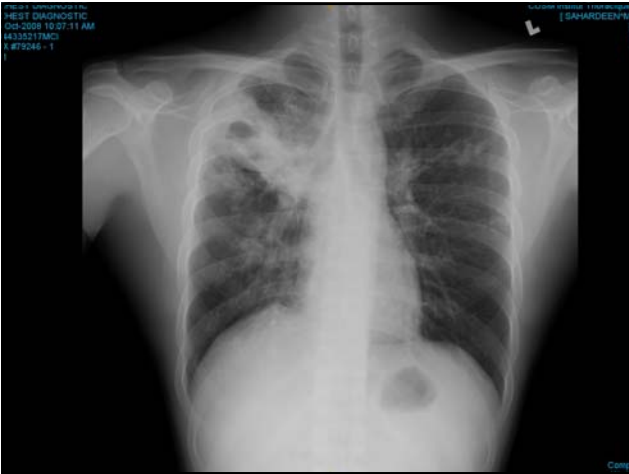
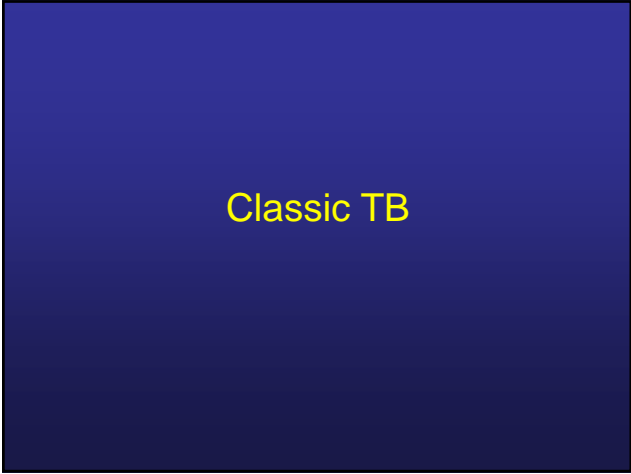
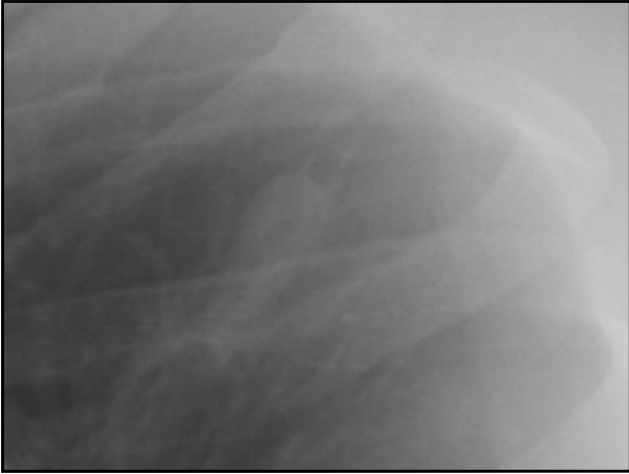
Radiology of TB

Dr Barry Rabinovitch
Montreal Chest Institute



Lordotic CXR





Minimal to extensive

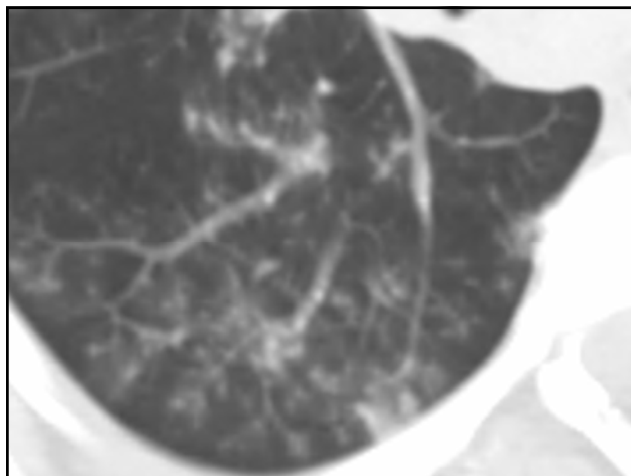
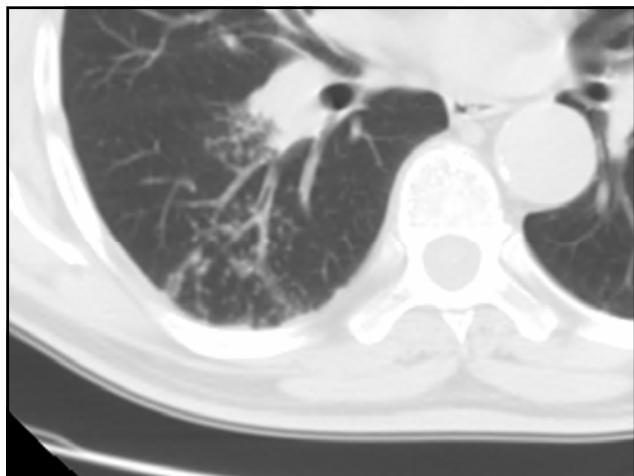
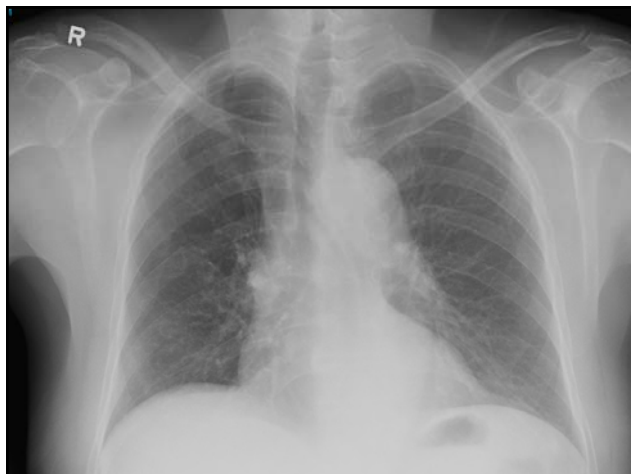
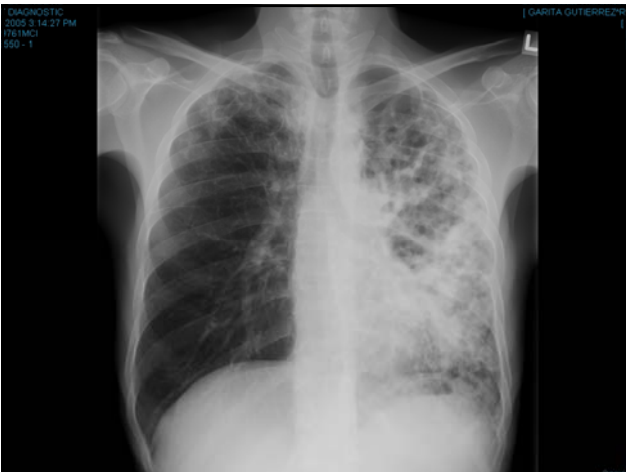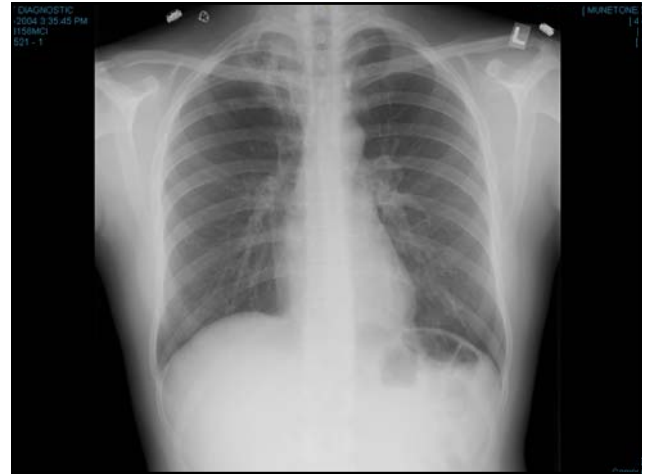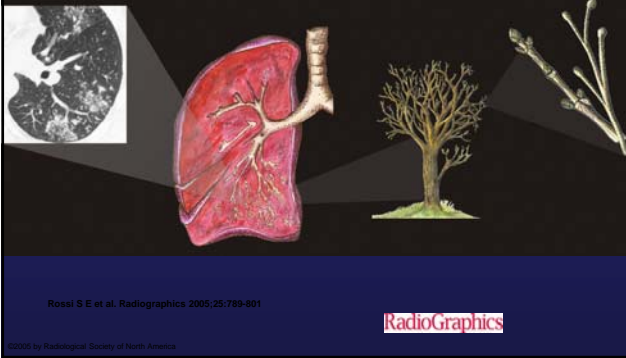
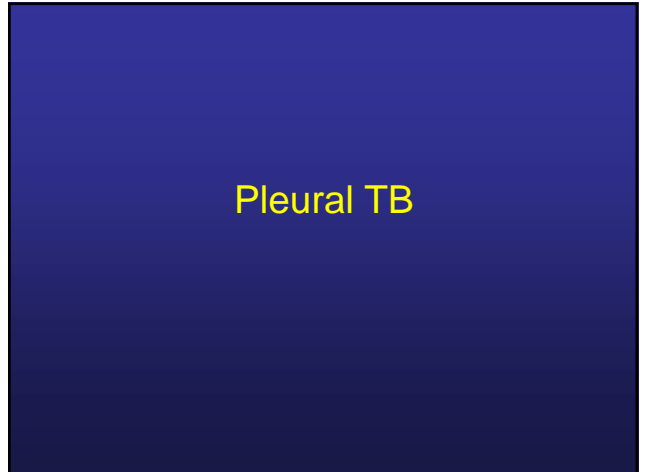
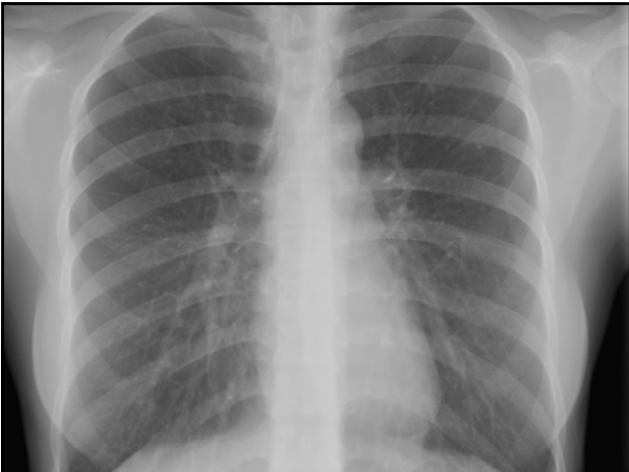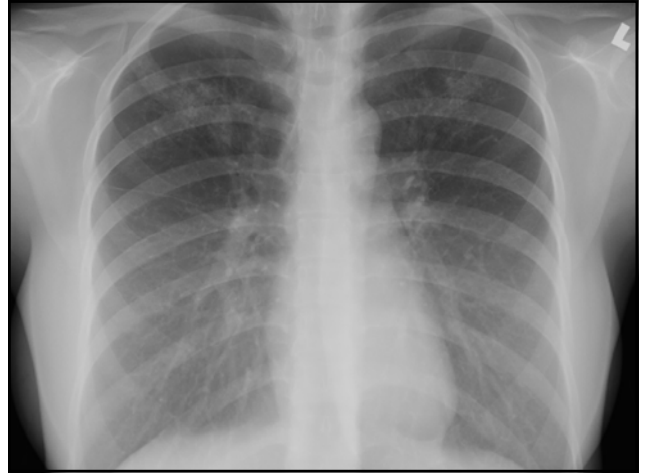
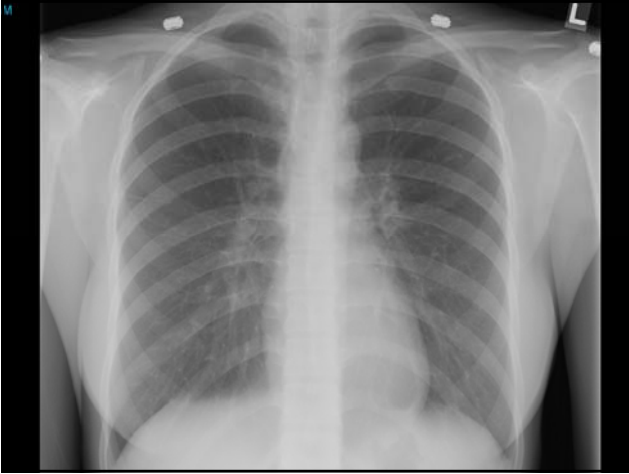
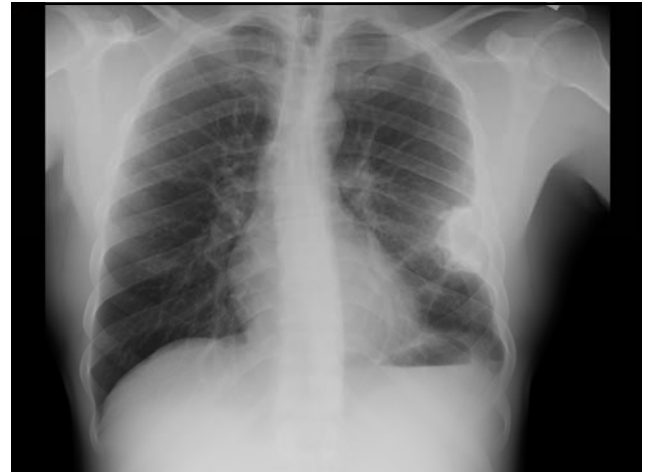
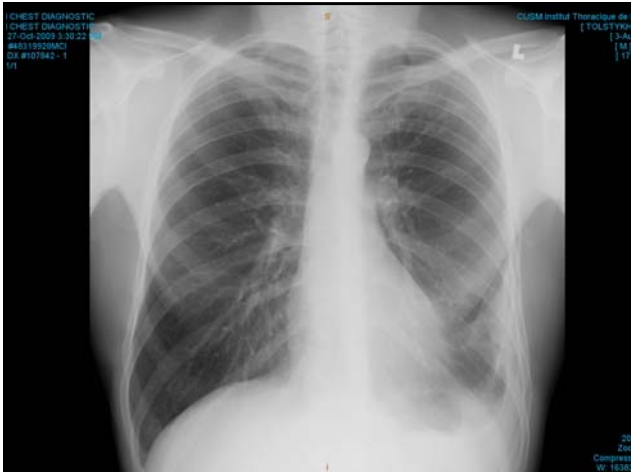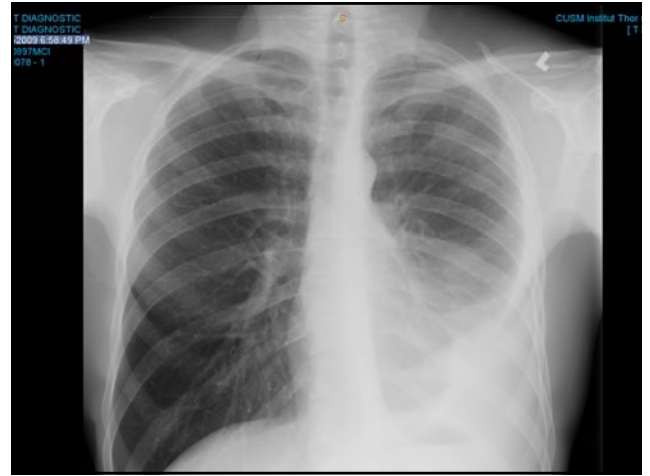
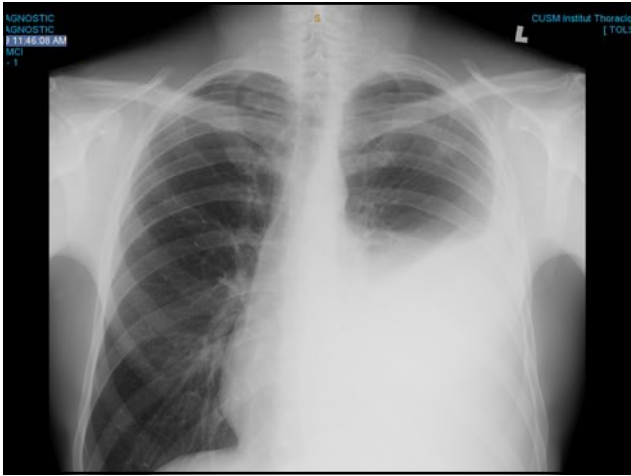


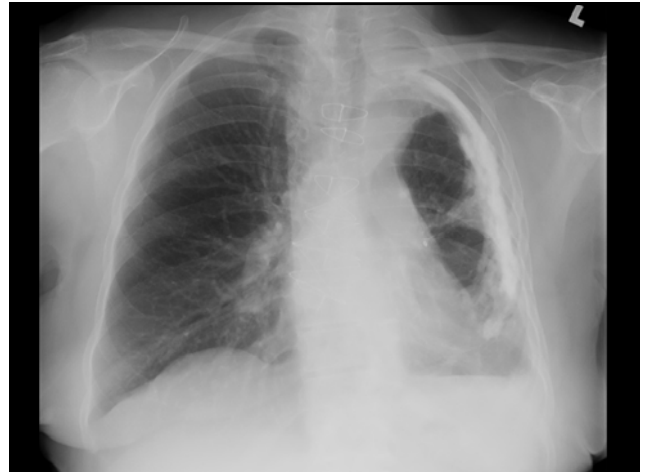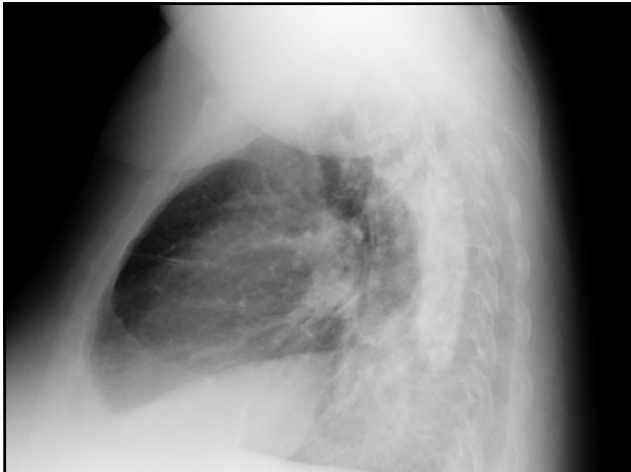
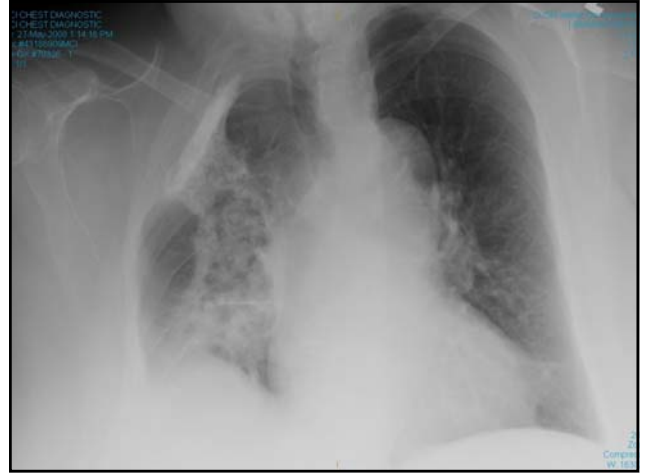
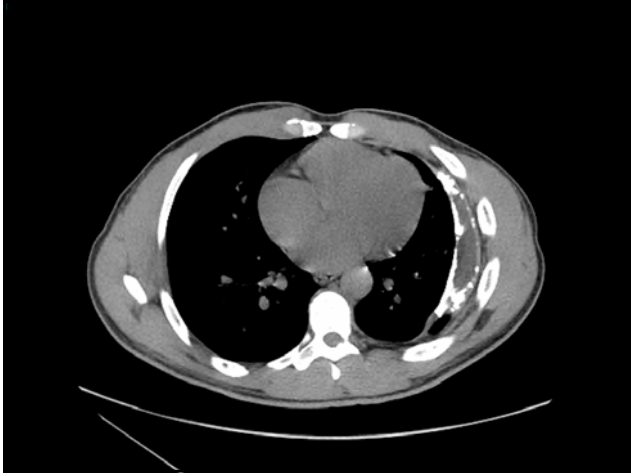Figure 1. High-resolution CT scan (far left) and drawings of the lung (middle left), a budding tree (middle right), and tree buds (far right) show the tree-in-bud pattern

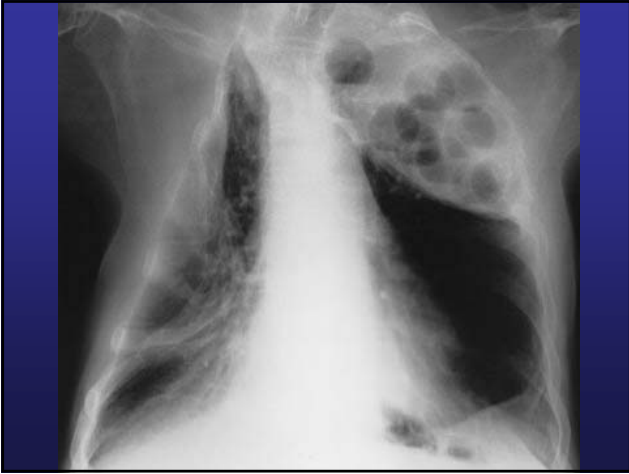


Latent to active

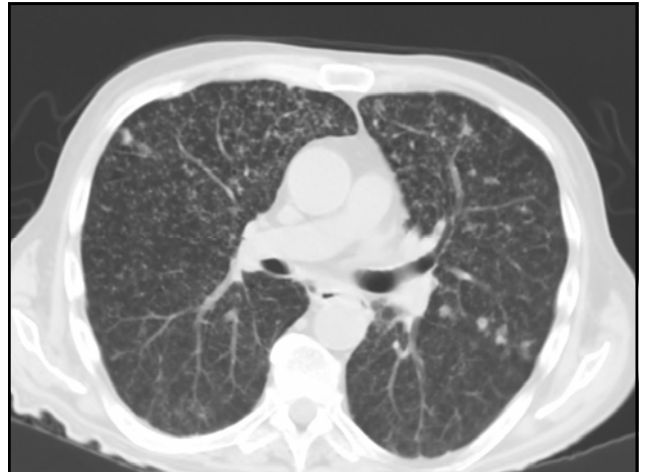
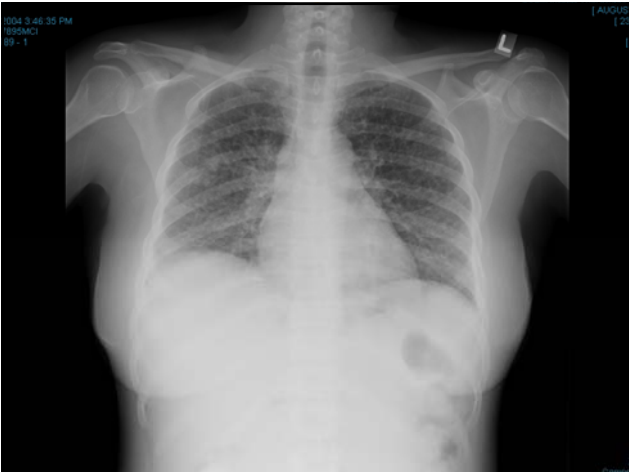



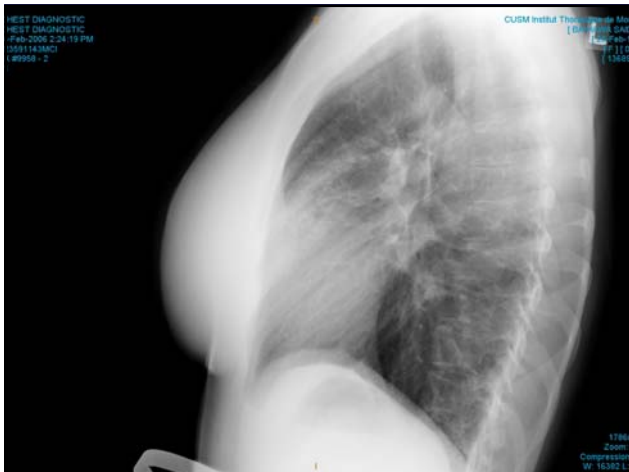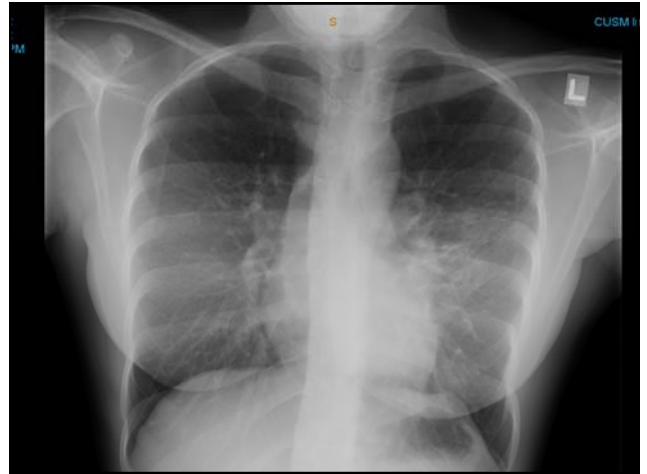




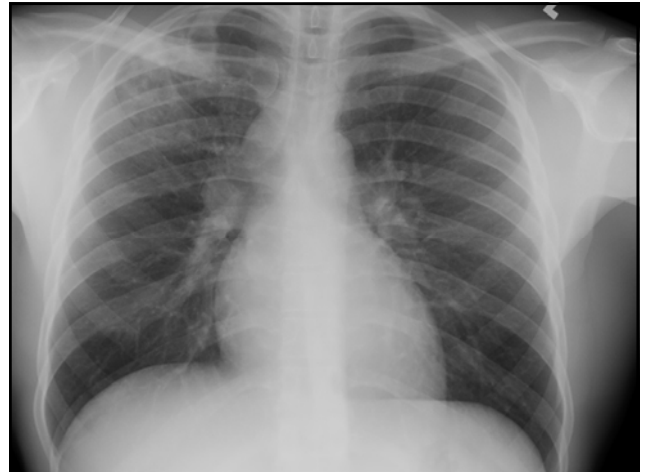
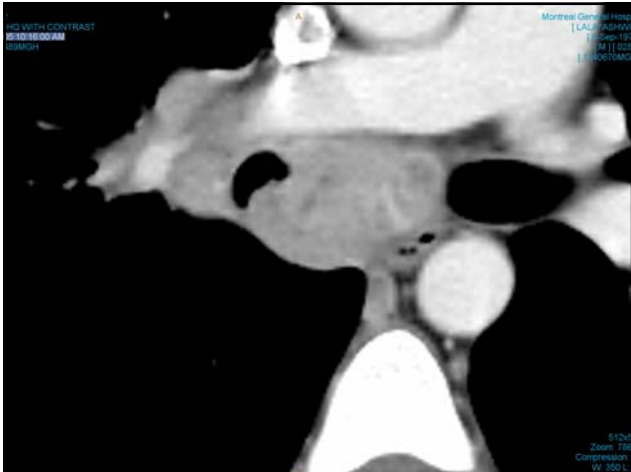
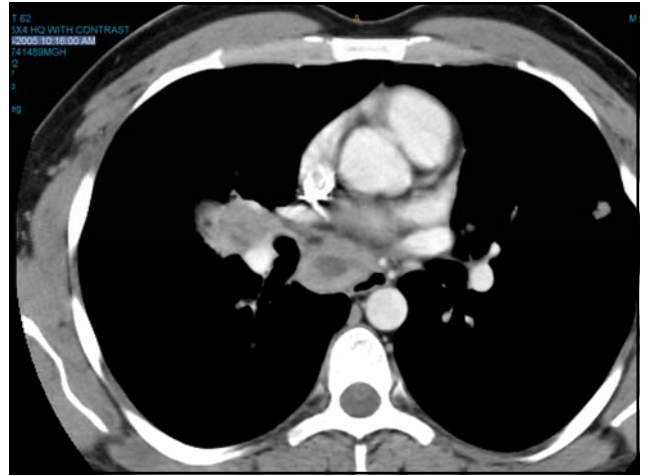
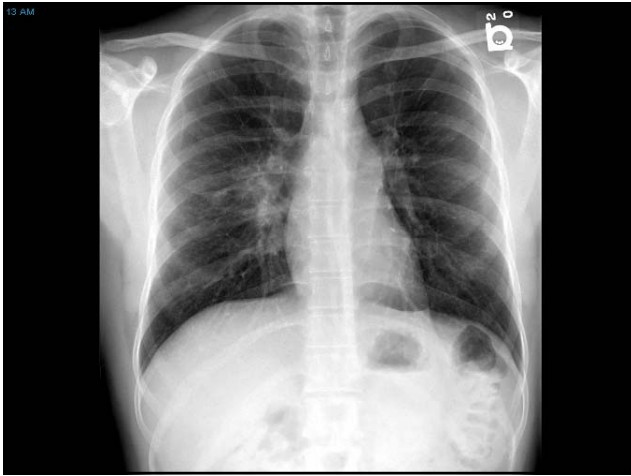
Miliary TB

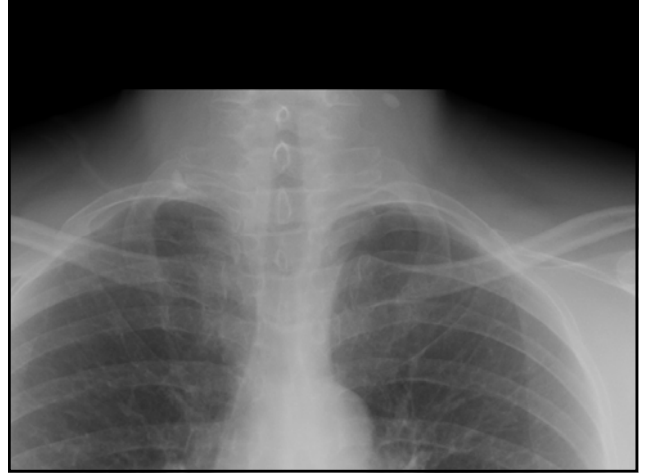
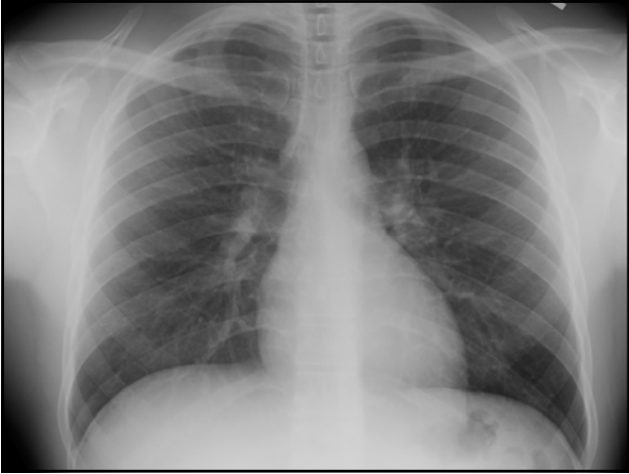


Primary TB

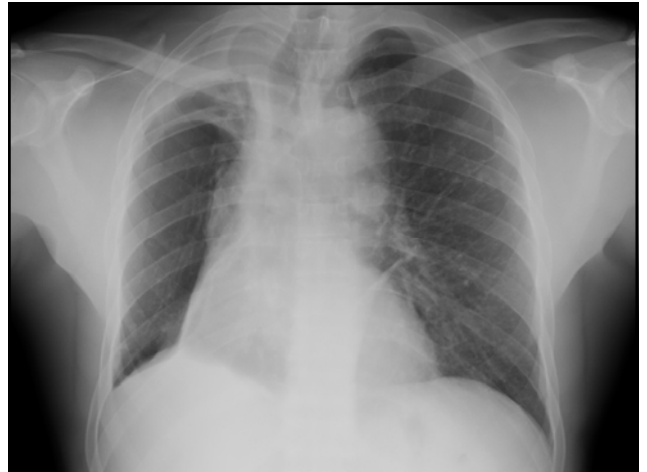

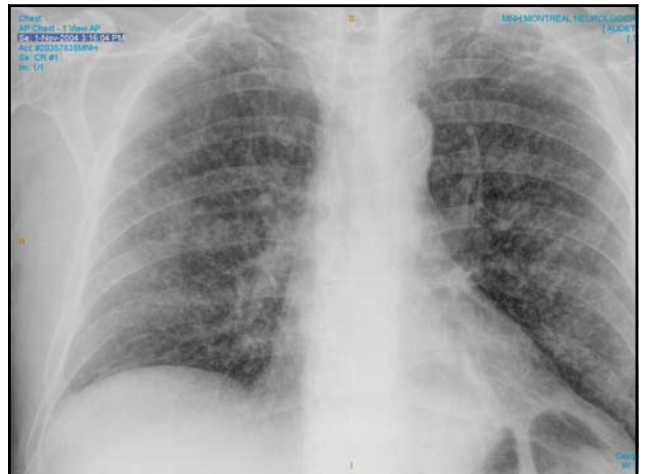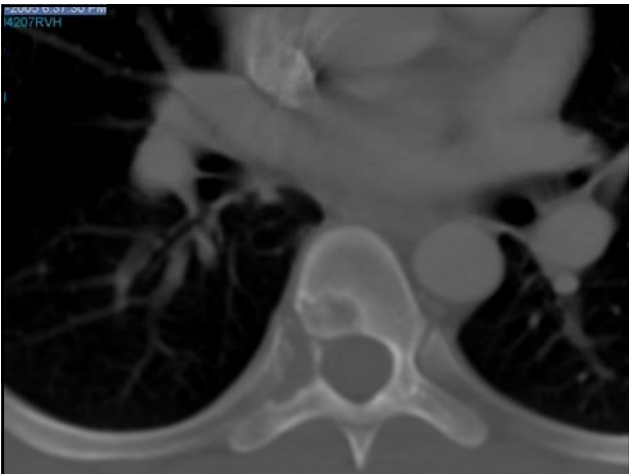
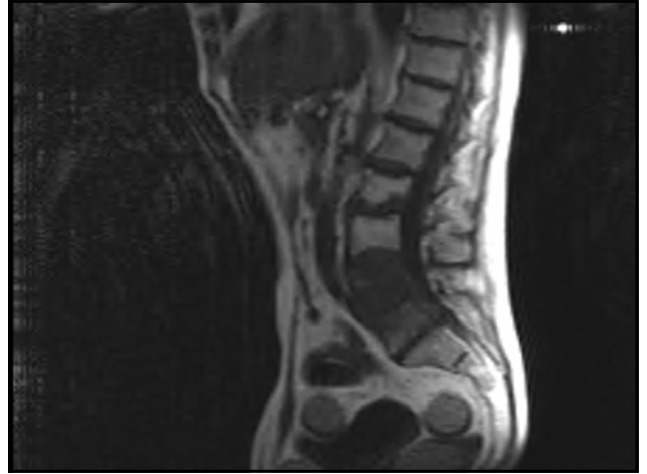
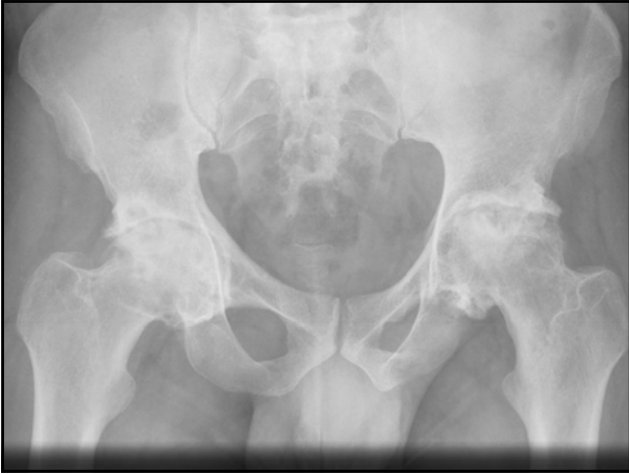
TB Adenopathy

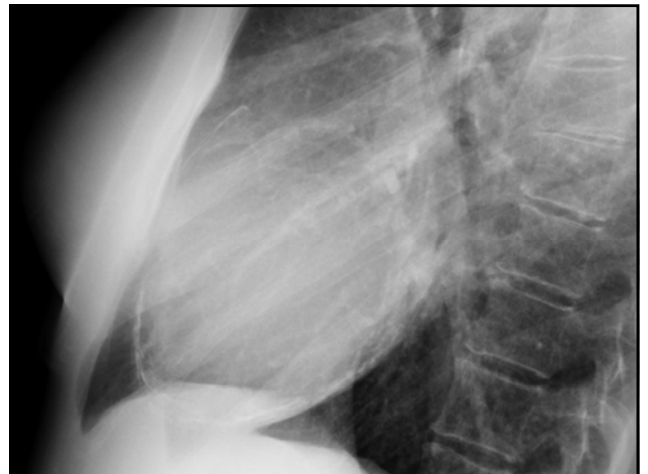
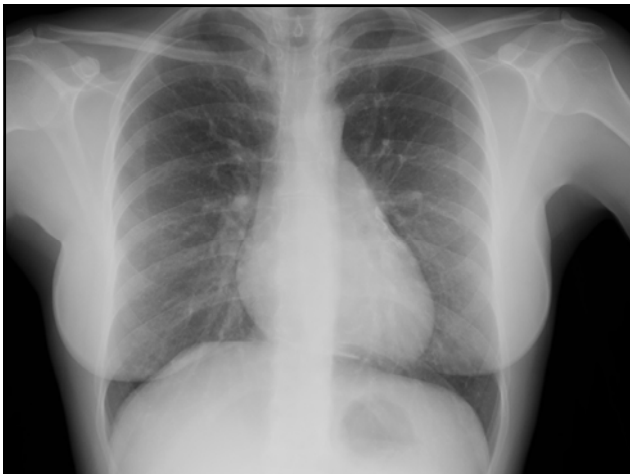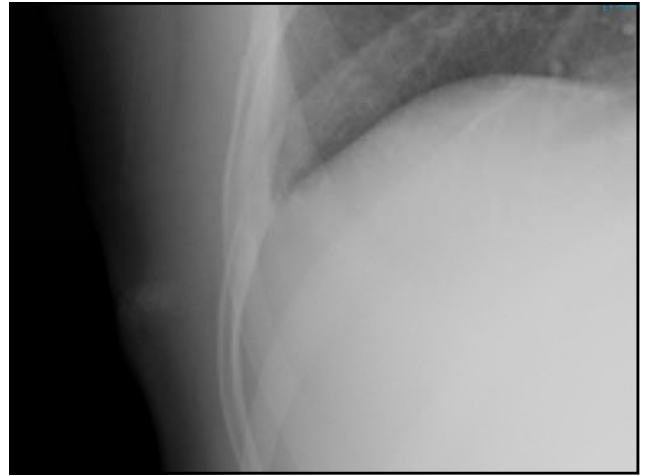
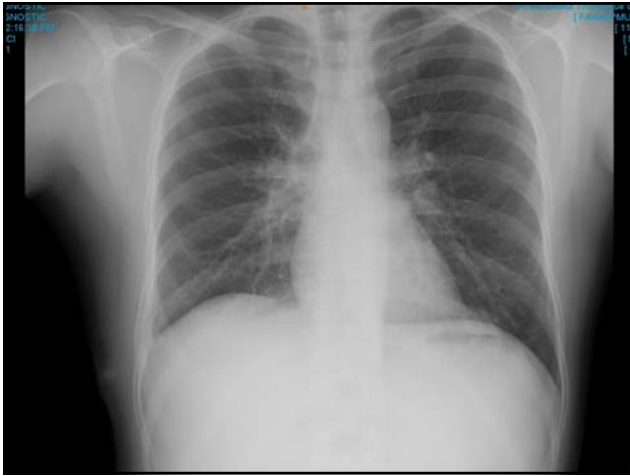




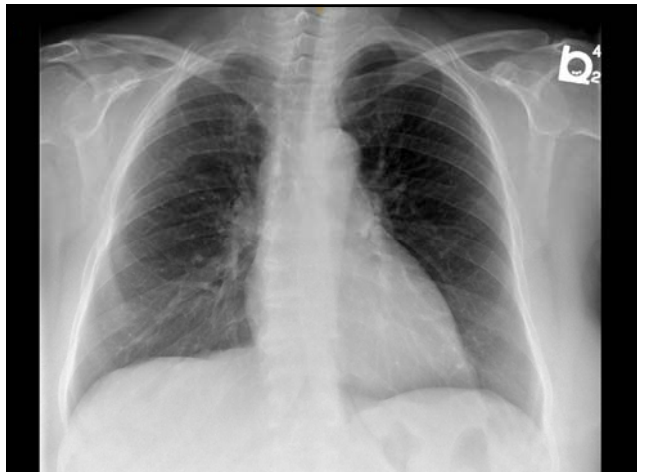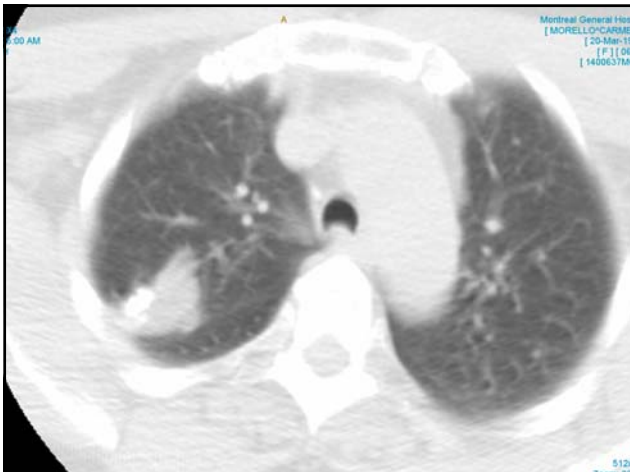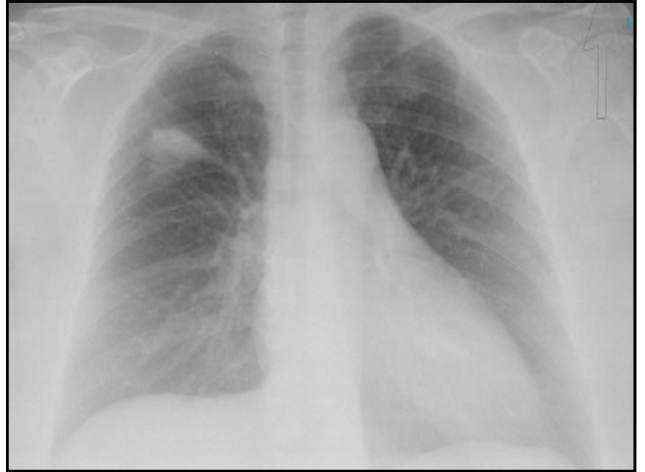Extrapulmonary TB

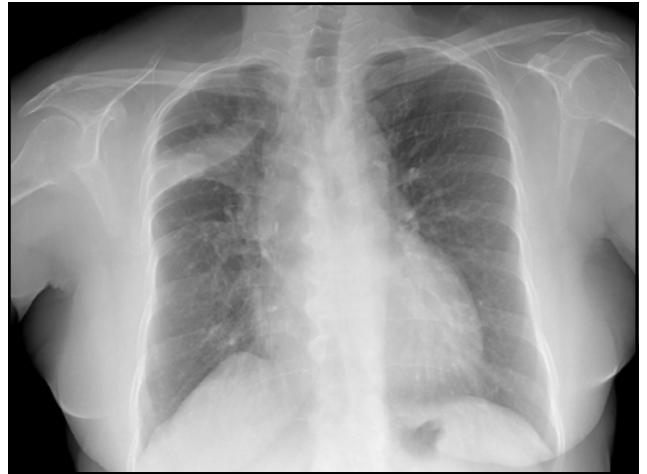
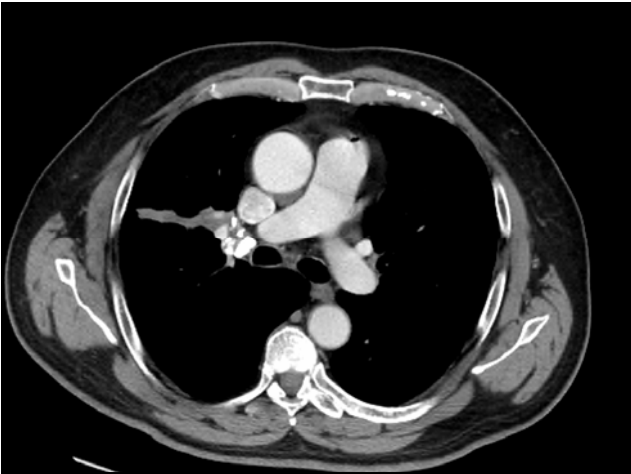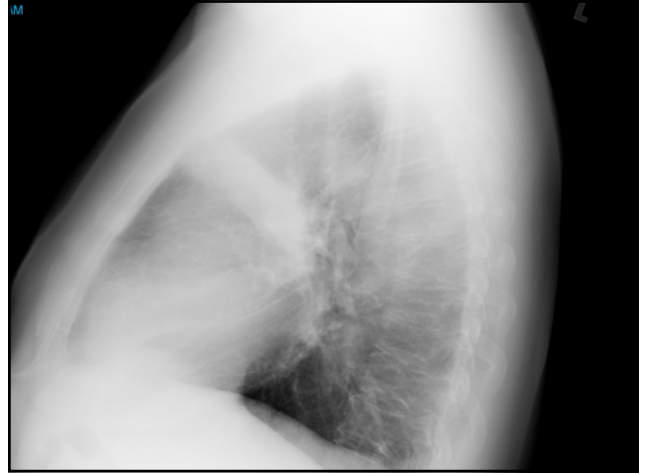
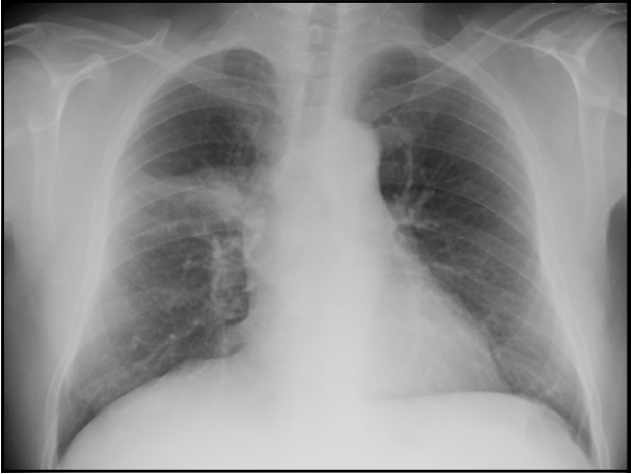


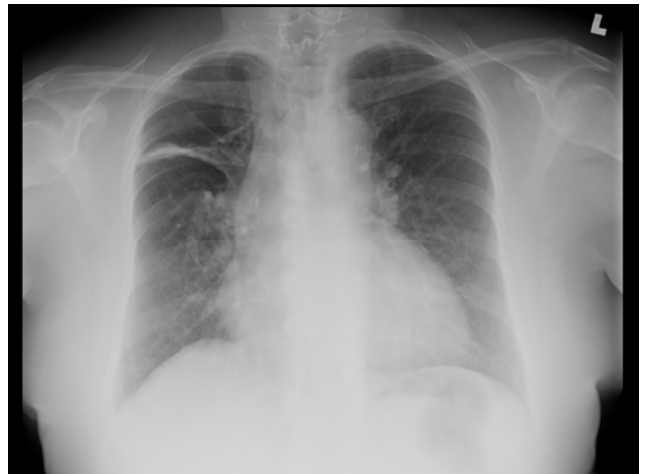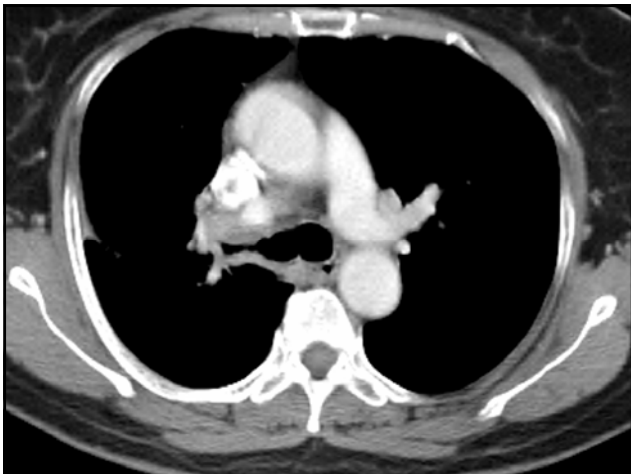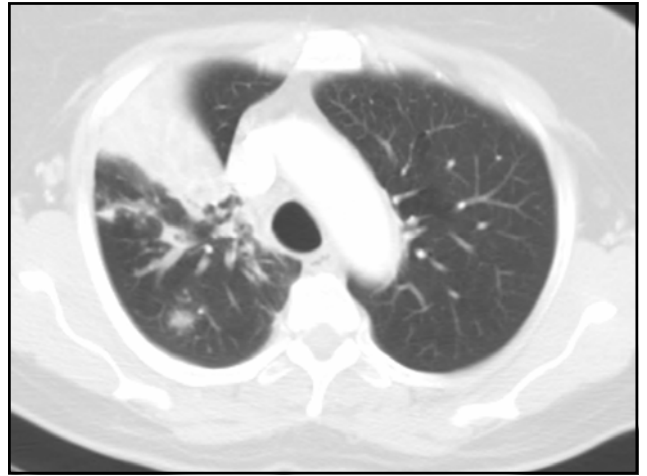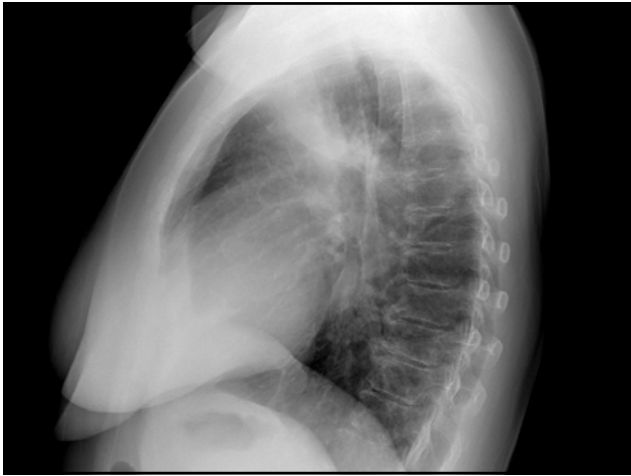


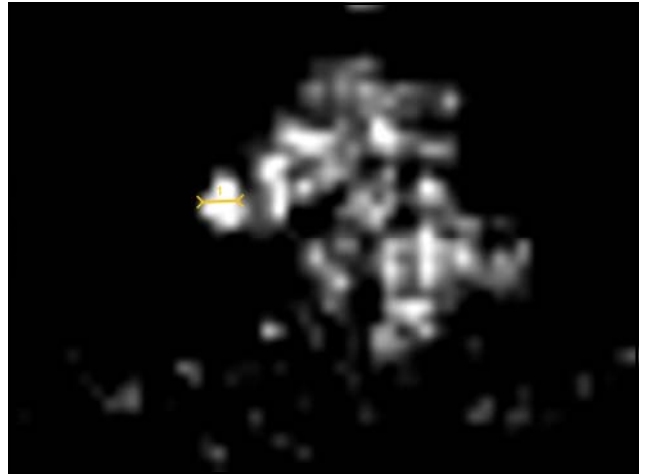
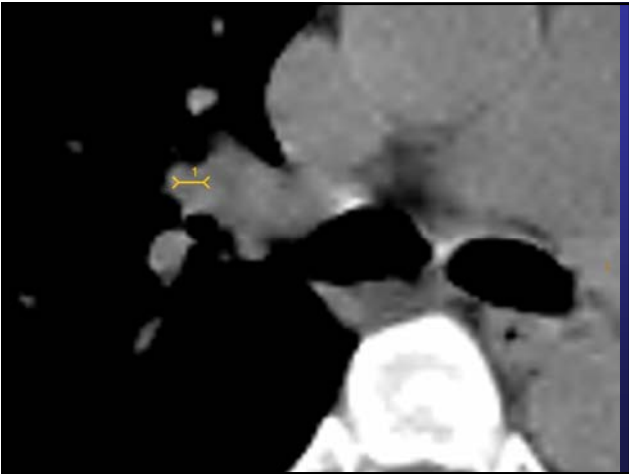
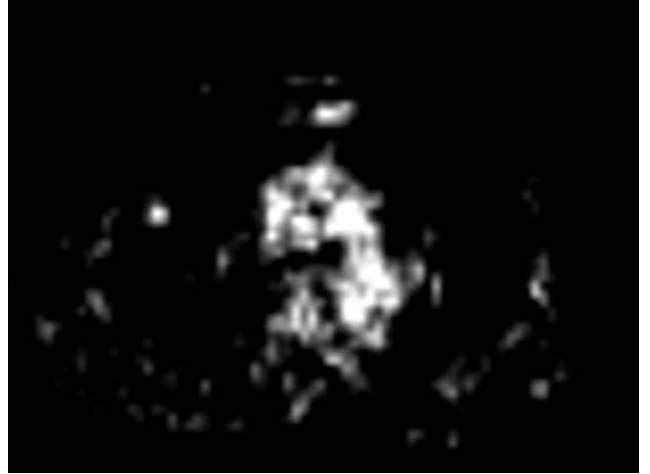
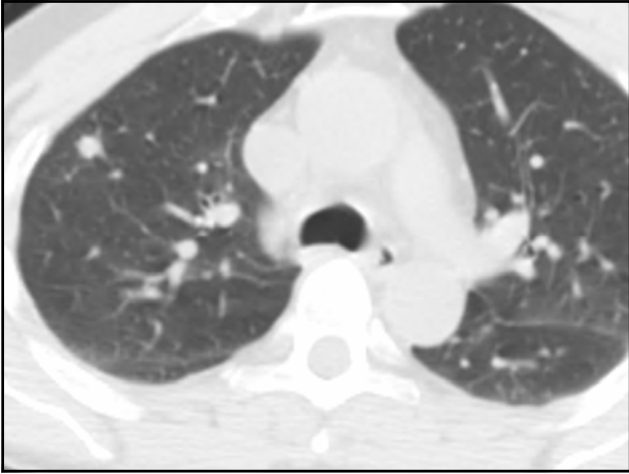


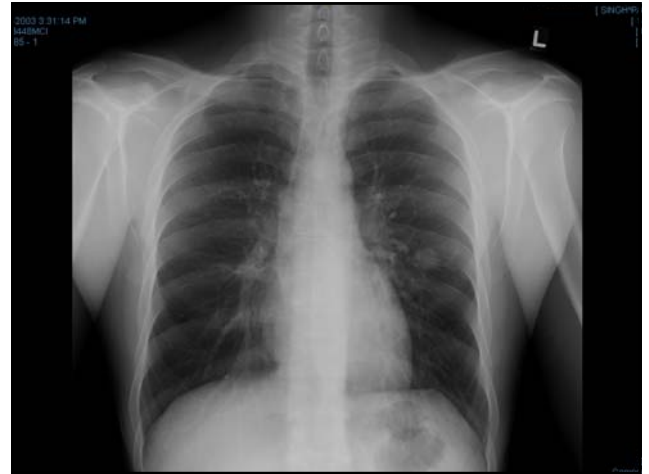
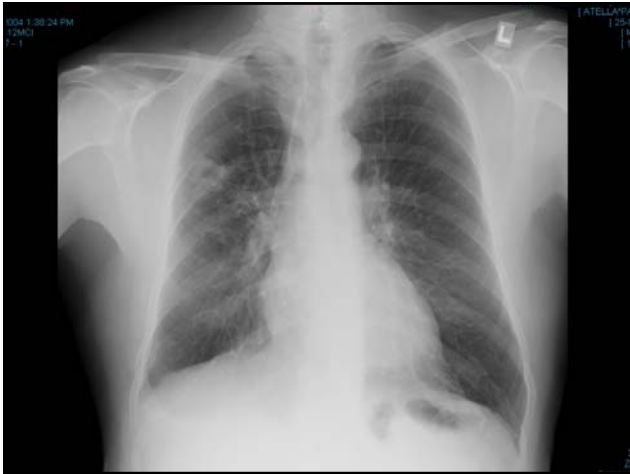- Looks like cancer
- But...



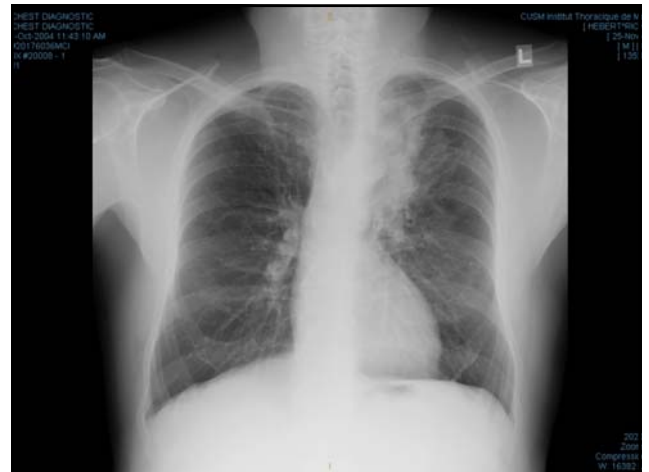

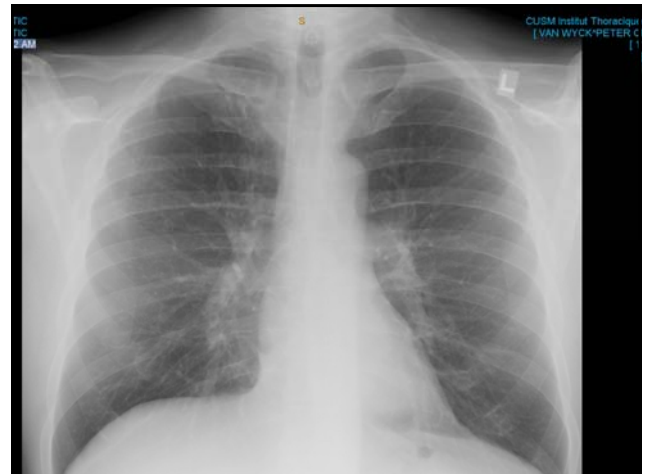
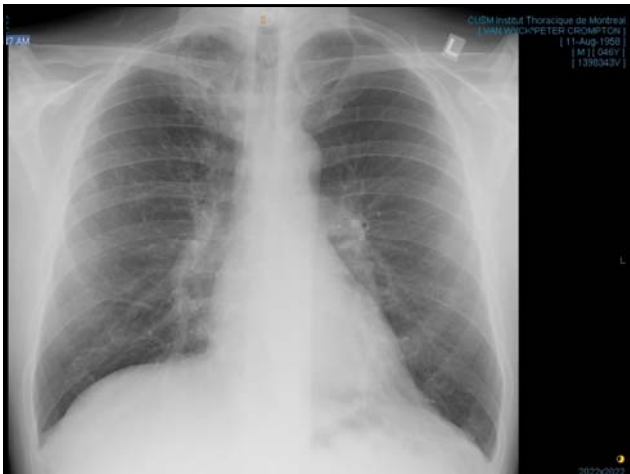
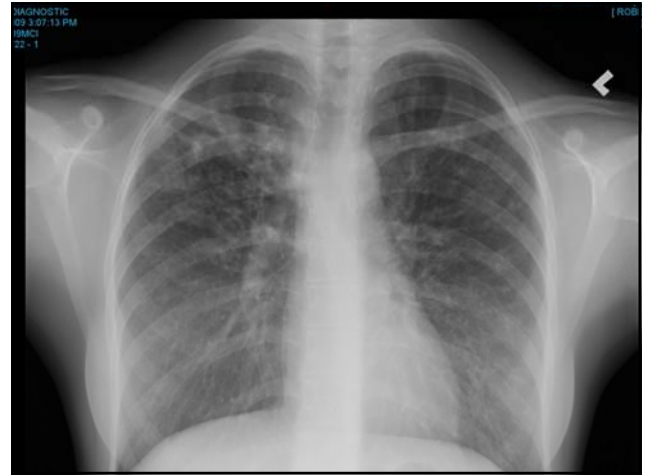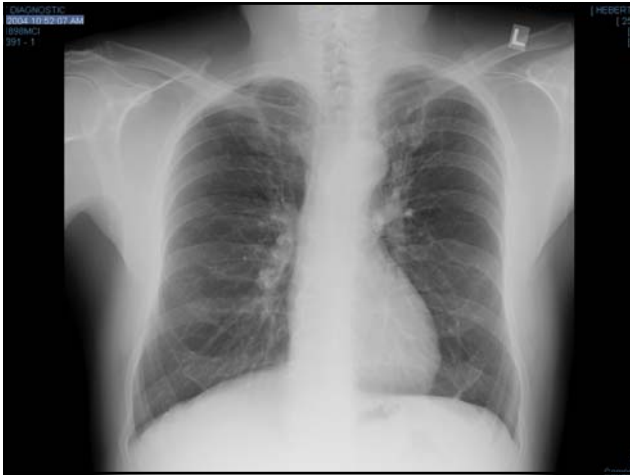




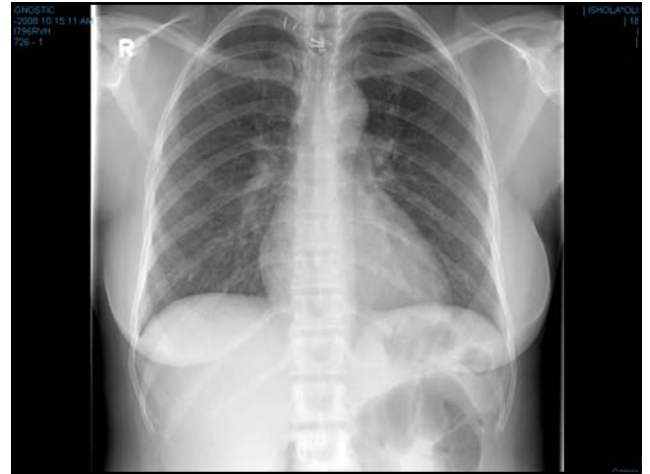
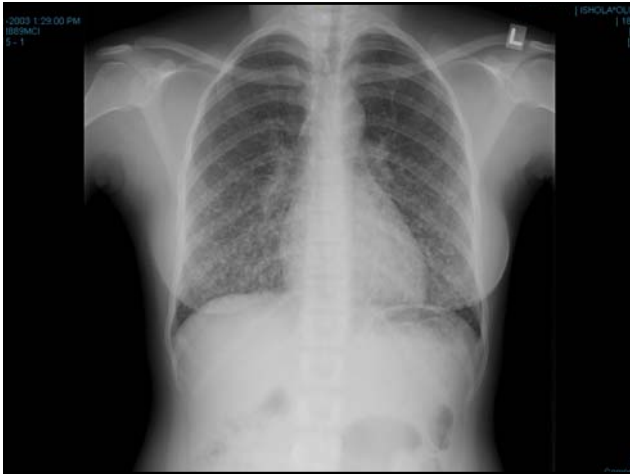
- Looks like TB
- But....







Bizarre TB



